


PRESENTING CLINICAL SIGNS

DATE History: Grade V/VI left to right-sided holosystolic murmur. Coughing more recently. Radiographs taken last month showed cardiomegaly with pulmonary venous congestion and pulmonary edema.
7/8/22 Currently receiving furosemide 12.5 mg BID and pimobendan (2.5 mg BID).

ECHOCARDIOGRAPHIC FINDINGS

PERFORMED BY: 2D, M-mode, and Doppler study.

Loetitia Saint-Jacques, RVT, LVT There is moderate left atrial dilation. The mitral valve leaflets are thickened, and a moderate jet of mitral regurgitation is present. There is moderate left ventricular dilation. Left ventricular systolic function is mildly hyperdynamic. The aorta and aortic valve are normal. Right atrial and right ventricular dimensions are normal. The tricuspid valve leaflets are mildly thickened, and a very mild jet of tricuspid regurgitation is present. TR velocity does not suggest the presence of pulmonary hypertension. The pulmonary artery and pulmonic valve are normal. No shunting lesions are visualized. No pericardial effusion or cardiac masses are seen.

INTERPRETED BY
Keith Blass, DVM, MS, DACVIM (Cardiology)

PATIENT
Zoe Evans
 LA - 37.9 mm
 LVIDd - 36.7 mm
 LVIDs - 20.9 mm
 FS - 43%
 LVOT - 1.56 m/s
 RVOT - 1.13 m/s
 TR - 2.36 m/s

SPECIES **ELECTROCARDIOGRAPHIC FINDINGS**

Canine A six lead ECG is submitted for review.

BREED
 HR: 120 bpm
 Rhythm: Sinus arrhythmia

Poodle Mix Sinus arrhythmia is present throughout this recording. The MEA is normal. All complex amplitudes and intervals are within normal limits. No premature beats or conduction blocks are seen.

RADIOGRAPHIC FINDINGS

SEX Three-view thoracic radiographs are submitted for review.

FS There is moderate left atrial and left ventricular enlargement. The pulmonary vessels are within normal limits. There is mild narrowing of the left mainstem bronchus. The pulmonary parenchyma and pleural space are within normal limits. The trachea is normal. The remainder of the thorax is unremarkable.

AGE

13 y

ASSESSMENT/RECOMMENDATIONS

Degenerative mitral and tricuspid valve disease

WEIGHT

21 lb

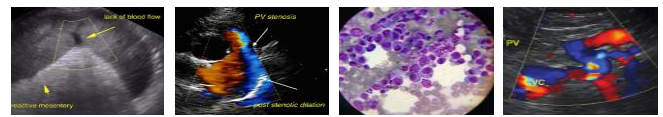
HOSPITAL NAME

Mountain View AH

Zoe's echocardiogram demonstrates regurgitation of blood across her mitral and tricuspid valves resulting from degenerative valve disease. Zoe's tricuspid valve disease is very mild, and is well-compensated at this time. Her mitral valve disease is more advanced, as Zoe has moderate mitral regurgitation present, with moderate secondary dilation of both her left atrium and left ventricle, though her left ventricular systolic function is well-preserved. Given the presence of moderate left heart chamber dilation, it's likely that mainstem bronchial compression is contributing to Zoe's cough (this appears to be present in her radiographs), and it comes as no surprise that she reportedly experienced an episode of left-sided congestive heart failure last month.

REFERRING VET

Dr. Kalivoda



Today's radiographs show that Zoe's congestive heart failure is currently controlled.

DATE

7/8/22

Zoe's current cardiac medications are appropriate, as is therapy with enalapril (5 mg BID) and spironolactone (12.5 mg BID).

A renal/electrolyte profile is recommended in 1-2 weeks. A recheck echocardiogram is recommended in 9 months. Repeat radiographs are recommended any time clinical signs compatible with congestive heart failure develop.

PERFORMED BY:

Loetitia Saint-Jacques, RVT, LVT

INTERPRETED BY

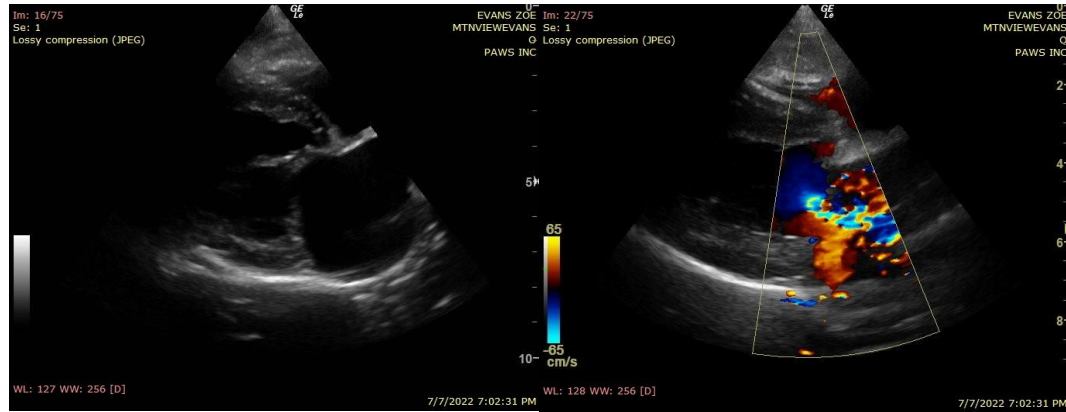
Keith Blass, DVM, MS, DACVIM (Cardiology)

PATIENT

Zoe Evans

SPECIES

Canine



The information and recommendations provided are based on the images presented by the referring veterinarian. No evaluation can be communicated regarding pathology that was not visible in the image/video clips provided.

BREED

Poodle Mix

Thank you for this referral. If the clinical or image interpretation does not parallel your findings or if I can be of any further assistance please contact me.

SEX

FS

Keith Blass, DVM, MS, DACVIM (Cardiology)
KeithBlass@gmail.com
631-804-5754

AGE

13 y

WEIGHT

21 lb

HOSPITAL NAME

Mountain View AH

REFERRING VET

Dr. Kalivoda